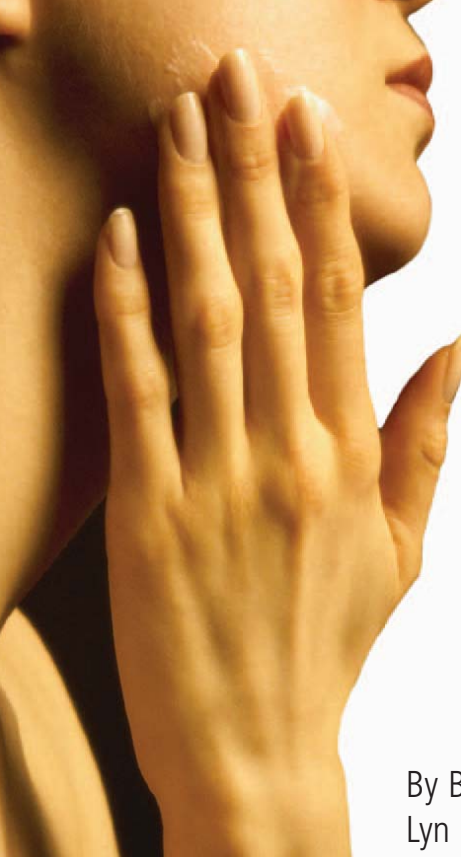



# Dealing with Common Skin Problems

By Benjamin Barankin, MD; and  
Lyn Guenther, MD, FRCPC

## In this article:

1. Taking a history.
2. The exam.
3. Common lexicons.

**S**kin problems represent approximately 15% to 20% of visits to primary-care providers, underlining the importance of a good foundation of knowledge about dermatology.<sup>1,2</sup> The diagnosis of a dermatologic problem is based significantly on the history and the physical examination. The importance of understanding and appropriately using dermatologic terminology is important both for note-taking and for referring a patient to a dermatologist.

## Taking a history

Focused history taking is imperative to explaining the nature of a skin lesion. There are key historical questions that should be asked

Table 1

### Approach to Describing Skin Lesions (LES T. CABS)

Location and distribution	Symmetrical, asymmetrical, sun-exposed flexural/extensor, acral (hands/feet)
Erythema	Erythematous or non-erythematous lesions and/or underlying skin
Surface Features	Smooth, scaly, warty, crusts
Type	Macule, papule, cyst, vesicle, pustule, ulcer
Colour	Pink, red, purple, white, brown, blue, yellow
Arrangement	Single or multiple, discrete, unilateral, generalised, disseminated, grouped, annular, linear, serpiginous
Border and shape	Well or poorly defined, active edge, round, oval, irregular, pedunculated
Special sites/systemic	Scalp, mouth, nails, genitalia, systemic disease and constitutional symptoms

# Common Skin Problems

Table 2

## Common Lexicons in Dermatology

Description	Definition	Example
Abscess	Accumulation of pus in the dermis or subcutaneous tissue.	<i>Staphylococcus aureus</i> infection.
Annular (arrangement)	Arranged in a ring shape.	Granuloma annulare.
Atrophy (type and surface feature)	Depressed surface due to a thinned epidermis and/or dermis and/or subcutis.	Lichen sclerosus et atrophicus, necrobiosis lipoidica diabetorum, prolonged potent steroid use.
Bulla (type)	Blister > 1 cm.	Bullous pemphigoid.
Burrow (type)	Linear "S" shaped papule 3 mm to 5 mm.	Scabies.
Comedo (type)	Plugged (pilo) sebaceous follicle: 1. Closed or whitehead 2. Open or blackhead	Bullous pemphigoid.
Crust (or scab) (surface feature)	Dried serum, pus or blood.	Impetigo, herpes simplex or zoster.
Cyst (type)	Sac containing fluid, cells or cell products (e.g., keratin).	Epidermal cyst, pilar cyst, or mucous cyst.
Ecchymosis ("bruise") (type)	Large confluent area of purpura.	Post-surgery or trauma.
Erosion (surface feature)	Partial loss of epidermis. Heals without scarring.	Eczema, lichen simplex, pemphigus vulgaris.
Erosion (surface feature)	Redness that blanches on pressure.	Sunburn, cellulitis, erysipelas, fifth disease, or erythroderma.
Erythema	Local damage due to scratching; consists of linear or pinpoint erosions or crusts.	Any pruritic lesion (e.g., poison ivy dermatitis).
Excoriation (surface feature)	Serum, blood or pus accumulated on skin surface.	Acute eczema, or contact allergic dermatitis.
Fissure (surface feature)	Linear split in epidermis or dermis.	Eczema, or thickened calluses.
Folliculitis (type)	Pustule (pus-filled lesion < 1 cm) involving a hair follicle. Hair is usually contained in the centre.	Folliculitis due to <i>Staphylococcus aureus</i> .

Continued on page 106.

# **LIPITOR**\*: Hitting targets.

**EFFICACY** ➤ †A powerful demonstrated effect across key lipid parameters<sup>1</sup>

Dr. Barankin is a dermatology resident at the University of Alberta, Edmonton, Alberta.

Dr. Guenther is a professor, dermatology department, University of Western Ontario. She is also medical director of the Guenther Dermatology Research Centre, president of the Canadian Society for Dermatologic Surgery, London, Ontario.

and they are most easily recalled by the mnemonic **ABCDEF PPP**.

**Acute or chronic?** Lesions that have been present for only a few hours or days need to be differentiated from those that have been present for long periods of time. For example, urticaria comes and goes within 24 hours, while leiomyomas (also red papules) are chronic. The time of onset can be helpful in differentiating photo eruptions. Solar urticaria onsets within five minutes of sun exposure and clears within one hour, whereas polymorphous light eruptions occur several hours after exposure and last several days.

**Behaviour:** Recurrence in the same location is typical for herpes simplex infections and fixed drug eruptions, which both typically last seven to 10 days.

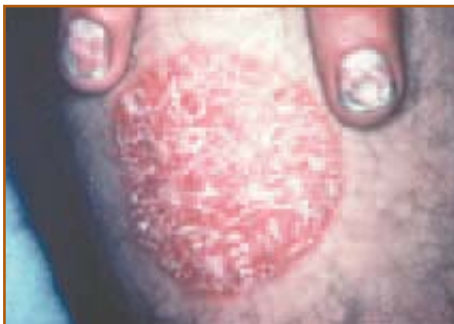

Figure 1. Psoriasis. Erythematous, circular plaque with dry, silvery-white scale and well-defined border. Note the associated nail changes.



**LIPITOR is an HMG-CoA reductase inhibitor (statin).** LIPITOR is indicated as an adjunct to lifestyle changes, including diet, for the reduction of elevated total cholesterol, LDL-C, TG and apolipoprotein B in hyperlipidemic and dyslipidemic conditions (including primary hypercholesterolemia, combined [mixed] hyperlipidemia, dysbetalipoproteinemia, hypertriglyceridemia and familial hypercholesterolemia) when response to diet and other non-pharmacological measures alone has been inadequate.

LIPITOR also raises HDL-cholesterol and therefore lowers the LDL-C/HDL-C and Total-C/HDL-C ratios (Fredrickson Type IIa and IIb). These changes in HDL-C with HMG-CoA reductase inhibitors should be considered as modest when compared to those observed in LDL-C and do not play a primary role in the lowering of LDL-C/HDL-C and Total-C/HDL-C ratios.

See Prescribing Information for complete warnings, precautions, dosing and administration.

LIPITOR is contraindicated: During pregnancy and lactation; active liver disease or unexplained persistent elevations of serum transaminases exceeding 3 times the upper limit of normal; hypersensitivity to any component of this medication.

# Common Skin Problems

Table 2 Continued

## Common Lexicons in Dermatology

Description	Definition	Example
Furuncle (type)	Deep necrotizing type of folliculitis.	Furuncle due to <i>Staphylococcus aureus</i> .
Keratin/Horn (surface feature)	Arranged in a ring shape.	Actinic keratosis, squamous cell carcinoma, wart, corn.
Lichenification (surface feature)	Rough, uneven surface due to a build-up of keratin. Difficult to pick off, unlike crust.	Atopic dermatitis, or lichen simplex chronicus.
Macule (type)	Thickened epidermis with increased skin markings due to rubbing.	Freckle, lentigo, tinea versicolor.
Nodule (type)	Flat, pigmented lesion < 1 cm. Raised lesion > 1 cm with rounded surface and thickness similar to diameter. Dried serum, pus or blood.	Erythema nodosum, keratoacanthoma, or prurigo nodularis.
Papule (type)	Raised lesion < 1 cm.	Acne vulgaris, rosacea, lichen planus, dermatofibroma, skin tags, or syringomas.
Patch (type)	Flat, pigmented lesion > 1 cm.	Café au lait patch, nevus of ota, port-wine stain, Mongolian spot, melasma.
Petechia (type)	Small, nonblanching, red-brown macules.	Capillaritis, meningococemia, externa or valsava pressure (e.g. vomiting).
Plaque (type)	Raised lesion > 1 cm (diameter > thickness).	Psoriasis, or a giant hairy nevus.
Purpura	Red, purple, and brown skin which doesn't fade with pressure.	Henoch-Schönlein purpura, or thrombocytopenic purpura.
Pustule (type)	Pus-filled lesion < 1 cm.	Acne vulgaris, rosacea, or pustular psoriasis.
Scaly (surface feature)	Dry and flaky surface.	Psoriasis, seborrheic dermatitis, tinea, ichthyosis.
Scar (cicatrix) (type and surface feature)	Healed dermal (or deeper) lesion two degrees to trauma or injury.	Hypertrophic scar, or keloid scar.
Sclerosis	Skin induration.	Morphea.
Serpiginous	Snake-like in appearance.	Elastosis perforans serpiginosa.

Continued on page 108.

**Change in size or colour:** Pigmented lesions that change in size and colour, particularly if the change is asymmetric, should raise the suspicion of melanoma.

**Discomfort:** Many skin conditions are asymptomatic. Itching and burning may be helpful symptoms, but can be variable. Itching, particularly at night, may suggest scabies, however, contact dermatitis, atopic dermatitis, lichen planus, and psoriasis can also be quite itchy. Burning pain is typical of herpes simplex and herpes zoster.

**External agents:** The sun can induce a number of eruptions. If window glass prevents a sun-induced eruption, ultraviolet B must be the cause since ultraviolet angle can pass through window glass. A walk through brush a few days before itchy eruption onsets may suggest poison ivy contact dermatitis. Detergents and chemicals and “protective” gloves can induce an allergic or irritant contact dermatitis. Does the skin condi-

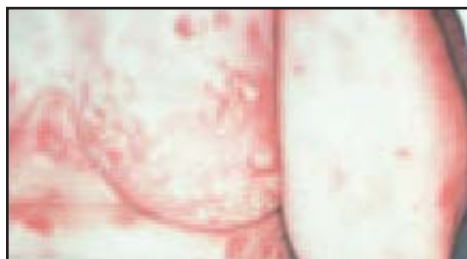

Figure 2. Pemphigus vulgaris. Disseminated, multiple, discrete, flaccid vesicles and bullae primarily on normal-appearing skin, erosions, and crusts.

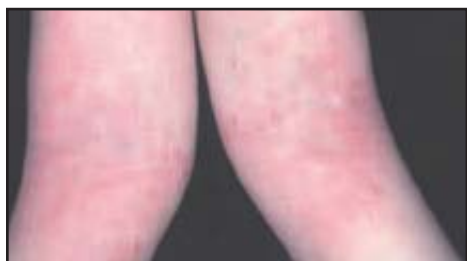

Figure 3. Atopic dermatitis. Adolescent with flexural (antecubital fossae) erythematous, poorly defined, scaly, lichenified plaques with excoriations.

## **LIPITOR<sup>®</sup>: Hitting targets.**

**EFFICACY** ➤ †A powerful demonstrated effect across key lipid parameters<sup>1</sup>

**EXPERIENCE** ➤ More than ~~40~~ **44** million patient-years of experience<sup>2†</sup>



Lipid levels should be monitored periodically and, if necessary, the dose of LIPITOR adjusted based on target lipid levels recommended by guidelines.

Caution should be exercised in severely hypercholesterolemic patients who are also renally impaired, elderly, or are concomitantly being administered digoxin or CYP 3A4 inhibitors.

Liver function tests should be performed before the initiation of treatment, and periodically thereafter. Special attention should be paid to patients who develop elevated serum transaminase levels, and in these patients, measurements should be repeated promptly and then performed more frequently.

The effects of atorvastatin-induced changes in lipoprotein levels, including reduction of serum cholesterol on cardiovascular morbidity, mortality, or total mortality have not been established.

† A patient-year represents the total time of exposure to LIPITOR as defined by the sum of each patient time on LIPITOR.<sup>5</sup>

# Common Skin Problems

Table 2

## Common Lexicons in Dermatology

Description	Definition	Example
Telangiectasia (type)	Small dilated blood vessels.	Rosacea.
Ulcer (type or surface feature)	Full-thickness, loss of epidermis and at least some dermis. Surface exudates and/or crusting will be present. Heals with scarring.	Elastosis perforans serpiginosa.
Umbilicated (surface feature)	Round depression in center of surface.	Molluscum contagiosum.
Vesicle (type)	Blister < 1 cm.	Chicken pox, herpes simplex, pemphigus vulgaris, hand and foot and mouth disease.
Warty/Papillomatous (surface feature)	Finger-like projections on the surface.	Wart, nevus sebaceous, seborrheic keratosis.
Wheals (type)	Transient swelling due to dermal edema (synonymous with urticaria).	Urticaria.

tion get better on holidays when there is no work exposure?

**Family history:** A number of conditions such as psoriasis and atopic dermatitis often run in families. Scabies and head lice can be spread by close contact and other family members may be infested.

**Pills and allergies:** An acute generalised eruption may be due to a medication, particularly if that medication was recently introduced. Medications and allergies also may help determine treatment since there could be drug interactions.

**Past history:** It is helpful to know if the patient has had the eruption before. Atopic dermatitis in adult life is often associated with a history of infantile atopic dermatitis. Guttate psoriasis is commonly recurrent after reoccurring streptococcal pharyngitis. Contact dermatitis and drug eruptions may

recur if there is repeat exposure.

**Previous treatments:** Response to previous treatments may help determine the etiology and future treatment. Although topical steroids may decrease inflammation and erythema, they may propagate fungal infections. Acute dermatitis and psoriasis are usually steroid responsive, but chronic disease may be more refractory.

## The exam

The physical examination of a patient is directed by the history. In addition to the examination of the area of complaint, it is often helpful to examine areas such as the scalp and other hair-bearing areas, as well as oral mucosa, genitalia, and nails. The appearance and palpation of individual lesions is important. There are certain characteristics of skin lesions that aid in the diagnosis. These qualities and characteristics are easily recalled using the

# Common Skin Problems

Table 3

## History of Plaque Psoriasis

- A:** Chronic with lesions persisting for months to years.
- B:** Lesions tend to persist, but may come and go. The same areas (*i.e.* elbows, knees, lumbosacral area and scalp) are usually affected, but any site can be affected.
- C:** Without treatment, the lesions usually persist unchanged, however, they may spread or clear.
- D:** Pruritus is common.
- E:** External agents do not usually have much impact, but harsh chemicals may cause irritation. Sun may improve the condition. Thirty per cent to 50% of patients have a history of developing psoriasis at areas of injury (Koebner's phenomenon).
- F:** Approximately 1/3 have a relative with the disease.
- P:** Beta blockers and lithium are among some of the medications that can aggravate psoriasis.
- P:** There is usually a history of a previous similar eruption.
- P:** Previous treatments for psoriasis may include topical steroids, tars, anthralin, calcipotriol, tazarotene, phototherapy and systemic medications.

## Description of Plaque Psoriasis

- L:** Symmetrically on the extensor surfaces including elbows, knees, and lumbosacral area, but can be anywhere on the skin.
- E:** Erythematous.
- S:** Dry, silvery-white scale.
- T:** Plaques.
- C:** Red.
- A:** Multiple, discrete, may be disseminated.
- B:** Well-defined border, circular-to-oval.
- S:** Scalp and nails frequently involved; arthritis common (in 5% to 8%).

Table 4

## History of Pemphigus Vulgaris

- A:** Chronic
- B:** Lesions come and go and can appear anywhere on the skin.
- C:** Lesions may extend when pressure is applied to the periphery.
- D:** Erosions are often painful.
- E:** Sun can aggravate the condition.
- F:** Family history negative. The patient may have an Ashkenazy Jewish background.<sup>11</sup>
- P:** Some drugs, including penicillamine and captopril, may induce pemphigus vulgaris.
- P:** Usually negative past history of similar rash.
- P:** Treatments include systemic steroids and other immunosuppressives.

## Description of Pemphigus Vulgaris

- L:** The skin may be clear and only the oral mucosa affected. Lesions may occur anywhere on the skin. The face, trunk, pressure points, groin and axillae are commonly affected.
- E:** Blisters usually develop on normal appearing skin, however, they may occur on erythematous skin. Eroded skin is erythematous.
- S:** Erosions and crusts.
- T:** Primary flaccid vesicles or bullae are often sparse because they rupture due to skin fragility; secondary painful erosions.
- C:** Clear fluid in the vesicles or bullae that appear on normal-appearing skin, or less commonly on an erythematous base. Eroded skin is red.
- A:** Disseminated, multiple, and discrete.
- B:** Well-defined borders. Lesions may spread at their periphery.
- S:** Mouth, scalp, and genitalia may be involved. Conjunctivae and esophagus are more rarely involved.

# Common Skin Problems

Table 5

## History of Atopic Dermatitis

- L:** Facial and extensor involvement in infants and young children while the diaper area is usually spared. As children get older there is localisation to the flexural areas. Generalised dryness.
- E:** Erythematous.
- S:** Rough, scaly surface, lichenified. Excoriations may be evident.
- T:** Papules, plaques, and patches; occasionally vesicles.
- C:** Pink-to-red.
- A:** Multiple, generalised.
- B:** Poorly-defined border.
- S:** In infancy, scalp involvement is common. Hyperlinear palms and soles. Nails may be very shiny due to persistent scratching. Eosinophilia and elevated serum IgE levels. Cataracts and keratoconus. Hay fever and asthma.

## Describing Atopic Dermatitis


- A:** Chronic or relapsing.
- B:** Lesions may come and go, but often persist in typical areas. In infancy, the face, scalp and extensor surfaces of the extremities are commonly affected, with sparing of the diaper area. In older children and adults, the flexural folds of the extremities are affected and chronic hand dermatitis may occur.
- C:** Lesions usually persist, but may clear and recur.
- D:** Pruritus is usually intense.
- E:** Irritants such as wool and detergents, excessive sweating, reduced humidity and allergens can aggravate the condition.
- F:** The family history is usually positive for atopic dermatitis, asthma and/or hay fever.
- P:** There is often a positive history of allergies.
- P:** In adults, there is often a history of infantile atopic dermatitis.
- P:** Previous treatments may include emollients, topical steroids, tars, tacrolimus and less commonly, phototherapy or systemic steroids/immunosuppressives.

mnemonic LES T. CABS (Table 1).

Once the elements of a focused history and physical examination are understood, the language of dermatology should be reviewed. One of the difficulties for many physicians is the proper description of skin lesions. Dermatology has a very rich descriptive language, yet an understanding and definition of 30 to 40 common descriptives is sufficient for most primary care providers (Table 2).

Using the History ABCDEF PPP and LES T. CABS physical examination mnemonics, and the appropriate dermatological lexicon, three classes of skin disease are described below.

**Plaque Psoriasis:** Psoriasis is a relatively common, chronic skin disease affecting approximately 2% of the population.<sup>3</sup> There are several variants of which plaque-type is the most common (Figure 1). Presentation is bimodal in the 30s and again in the



# ANXIOUS TO FIND OUT MORE?

Look for our ad in this issue.

ONCE - DAILY  
**EFFEXOR XR**  
venlafaxine HCl Extended Release Capsules

Product monograph available upon request.





# Common Skin Problems

## Take-home message

- An organised approach to the history and physical examination of skin lesions, coupled with the use of appropriate terminology, will result in an improved understanding of the presenting problem.
- Not only will it be easier to develop a more complete differential diagnosis, but also chart notes, referral requests, and the medical care of the patient will greatly benefit.

late 50s of life (Table 3).<sup>4</sup>

**Pemphigus Vulgaris:** This is an uncommon autoimmune disease of the skin and mucous membranes, resulting in superficial blisters and erosions (Figure 2). Pemphigus vulgaris is the most common form of pemphigus, with other variants including pemphigus foliaceus and paraneoplastic pemphigus.<sup>5</sup> Oral erosions are painful and found anywhere in the oral cavity.<sup>6</sup> Hoarseness may result from laryngeal involvement (Table 4).<sup>7</sup>

**Atopic dermatitis:** This is a chronically relapsing skin disease that affects 10% to 20% of children.<sup>8,9</sup> It is commonly associated with asthma or hay fever (Table 5). It typically presents in infancy, after two months of age. Many experience remission or considerable improvement by adolescence, although approximately 25% will continue to have relapses during adult life (Figure 3).

Other features include xerosis, keratosis pilaris, cheilitis, susceptibility to cutaneous infections, pityriasis alba, infraorbital fold, orbital darkening, wool intolerance, white dermatographism, elevated serum IgE and peripheral blood eosinophilia.<sup>10</sup> Patients may present with an acute (pruritic, erythematous papules and vesicles with underlying erythematous skin), subacute (erythema, excoriation, or scaling), or chronic (lichenification, prurigo nodularis) lesions.

## References

1. Julian CG: Dermatology in general practice. Br J Dermatol 1998; 141(3):518-20.
2. Morgan VA: Skin disease in general practice. Australas J Dermatol 1992; 33: 113-5.
3. Nall L: Epidemiologic strategies in psoriasis research. Int J Dermatol 1994; 33:313-9.
4. Fitzpatrick T, Johnson R, Wolff K, et al: *Color atlas and synopsis of clinical dermatology*. Third Edition. McGraw-Hill, Toronto, 1997.
5. Gannon T: Dermatologic emergencies. When early recognition can be lifesaving. Postgrad Med 1994; 96:67-5, 79.
6. Olson CL: Blistering disorders. Which ones can be deadly? Postgrad Med 1994; 96:53-4.
7. Hale EK, Bystryn JC: Laryngeal and nasal involvement in pemphigus vulgaris. J Am Acad Dermatol 2001; 44:609-11.
8. Laughter D, Istvan JA, Tofte SJ, et al: The prevalence of atopic dermatitis in Oregon schoolchildren. J Am Acad Dermatol 2000; 43:649-55.
9. Leung DY, Diaz LA, DeLeo V, et al: Allergic and immunologic skin disorders. JAMA 1997; 278: 1914-23.
10. Corrales CE, Walker C, Murphy L, et al: Atopic dermatitis: a review of diagnosis and treatment. Am Fam Physician 1999; 60: 1191-10.
11. Rye B, Webb JM: Autoimmune bullous diseases Am Fam Physician 1997; 55:2709-18.

**ADVAIR**  
salmeterol xinafoate / fluticasone propionate

# Asthma Control.

Now available in **DISKUS<sup>®</sup>** and **MDI**.



<sup>®</sup>ADVAIR<sup>™</sup> is indicated for the maintenance treatment of asthma in patients, where the use of a combination product is appropriate. This may include patients on effective maintenance doses of long-acting  $\beta_2$ -agonists and inhaled corticosteroids or patients who are symptomatic on current inhaled corticosteroid therapy. <sup>®</sup>ADVAIR<sup>™</sup> should not be used to treat acute asthmatic symptoms.<sup>1</sup>

<sup>®</sup>ADVAIR<sup>™</sup> DISKUS<sup>®</sup> contains lactose and is contraindicated in patients with IgE mediated allergic reactions to lactose or milk.

In adolescents and adults, the most common side effects are throat irritation (2%), hoarseness/dysphonia (2%), headache (2%), and candidiasis (2%) which can be reduced by rinsing and gargling with water after inhalation; and palpitations ( $\leq$ 1%). In children aged 4 to 11, the only adverse event with an incidence of  $>$ 2% was candidiasis.

HPA-axis function and hematological status should be assessed periodically. Height should also be regularly monitored in children and adolescents receiving prolonged treatment with inhaled corticosteroids.

<sup>®</sup>ADVAIR<sup>™</sup> is available in 2 dosage forms, <sup>®</sup>ADVAIR<sup>™</sup> DISKUS<sup>®</sup>, for patients 4 years and older and <sup>®</sup>ADVAIR<sup>™</sup> Inhalation Aerosol for patients 12 years and older.

**Reference:** 1. Product Monograph of <sup>®</sup>ADVAIR<sup>™</sup>, GlaxoSmithKline Inc., December 2001

<sup>®</sup>ADVAIR<sup>™</sup> used under license by GlaxoSmithKline Inc. DISKUS<sup>®</sup> is a registered trademark, used under license by GlaxoSmithKline Inc.<sup>®</sup> The appearance, namely the color, shape, and size of the DISKUS<sup>®</sup> inhalation device, is used under license by GlaxoSmithKline Inc.

GlaxoSmithKline Member

# Frequently Asked Questions



## Dealing With Common Skin Problems

Benjamin Barankin, MD;  
and Lyn Guenther, MD  
FRCPC

### 1. How do I take a history?

History-taking includes observing whether the lesion is acute or chronic, and studying the behaviour of the lesion. It is also good to ask the patient if the lesion has changed size or colour, whether the lesion causes discomfort, and whether there are any external agents which affect the lesion. Other important information is the patient's family history, the patient's medication and allergies, whether the patient has had the same lesion in the past, and how the patient responded to previous treatment.

### 2. How many patients present with skin problems?

Skin problems represent approximately 15% to 20% of all visits to primary-care providers.

### 3. What do I look for on physical exam?

Look at the location and distribution of the lesion, whether there is erythema, what the surface features are, the type of lesion, the colour of the lesion, the arrangement of the lesion, the border and shape of the lesion, and special sites affected by the lesion.

For an in-depth article  
on common skin problems,  
please go to page 102.