

---

# A Systematic Approach To Adult Hip Pain, Part 1

In this two-part article, adult hip pain will be reviewed from the inside out. The first part will take a look at the anatomy and biomechanics affecting the hip, as well as the approach to evaluation hip pain. Next month in the second part, common conditions that cause hip pain will be examined.

By Robert Wang, BSc, Mohit Bhandari, MD, MSc, and Richard J. Lachowski, MD, FRCPC

---

**A**dult hip pain is a common problem, affecting over 25% of people with joint-related pain. The complex anatomy of the hip joint and surrounding soft tissues offers challenges to diagnosing and appropriately treating a painful hip. Failure to diagnose and appropriately manage injuries of the pelvis can result in prolonged patient morbidity and, in some cases, mortality. A systematic approach to adult hip pain, including a careful clinical and radiographic examination, will identify the majority of all clinically important pathologies in this region.

One of every 10 patients with joint pain complain of a painful hip. As a major

weight-bearing joint, the hip supports the entire upper body. At the same time, however, it allows for a flexible degree of movement between the lower limbs and the upper body. Any pathology affecting the hip is particularly debilitating because it compromises the patient's ability to ambulate.

Determining the cause of a painful hip can be a major challenge to physicians. A careful history, physical examination and appropriate investigations can identify the majority of hip ailments. The purpose of this review article is to provide a systematic approach in the evaluation of hip pain in the adult patient.

---

# Adult Hip Pain

## Anatomy and Biomechanics

### *Hip Anatomy*

The hip joint is the largest joint in the body, and consists of the femoral head articulating with the acetabulum. This ball-and-socket configuration permits a wide range of motion, however, the stability is maintained by several structures that encase the joint. Excessive range of motion, without anatomic stability, results in subluxations or dislocations. The acetabulum, the hip capsule, and muscles stabilize the joint as it moves through a wide range of motion.

The acetabular labrum is a fibrocartilagenous structure. It functions to deepen the socket, to provide a greater

degree of articulation between the femoral head and acetabulum. The articular surface of the acetabulum is horseshoe-shaped, surrounding a nonarticular central depression known as the acetabular fossa. An articular fat pad occupies the fossa, and can become impinged in some patients. The femoral head is covered with articular cartilage, except at the fovea centralis, where the ligamentum teres is attached. The thickest layers of both femoral and acetabular cartilage are seen in apposition at the superior and slightly anterior joint surfaces, corresponding to the area receiving the greatest weight-bearing stress.<sup>1</sup>

The hip joint is enclosed by a strong fibrous capsule, which is made of four ligaments: iliofemoral ligament, pubofemoral ligament, ischiofemoral ligament and ligament teres. Figure 1 illustrates the joint capsule and its sites of attachment. The ligaments function to prevent extremes of motion. They become taut, for example, during the limits of extension to prevent hyperextension.


Muscles around the hip help to coordinate its wide range of motion. Hip flexion is performed by the iliopsoas and the quadri-



Dr. Wang is research assistant, division of orthopedic surgery, department of surgery, McMaster University, Hamilton, Ontario.



Dr. Bhandari is fellow of the clinician scientist program, division of orthopedic surgery, department of surgery, and department of clinical epidemiology and biostatistics, McMaster University, Hamilton, Ontario.



Dr. Lachowski is associate clinical professor, division of orthopedic surgery, department of surgery, McMaster University, Hamilton, Ontario.

---

ceps, while hip extension is primarily the function of the hamstrings. Other muscles abduct, adduct, internally rotate and externally rotate the hip. Bursae reduce friction in areas where muscle slides over tendon or bone. There are many bursae in the hip joint, however, only the greater trochanteric, iliopsoas and ischiogluteal bursae seem to have clinical significance (Figure 1).<sup>2</sup>

### **Biomechanics and Gait**

The hip is subject to considerable stress over a lifetime from movement, weight bearing and repetitive impact. Any derangement in the smooth gliding of the joint surfaces can cause deterioration of cartilage and, subsequently, of the joint. The hip moves in a combination of three basic planes: flexion and extension, abduction and adduction (side-to-side), and external and internal rotation. The muscles that hold us erect and allow walking and stair climbing exert considerable forces across the hip in the range of three to six times body weight.<sup>3</sup> Thus, a 25-pound weight gain may seem like 150 additional pounds to the hip.

The lower extremities are dedicated to the important tasks of weight bearing and ambulation. A gait abnormality is usually a consequence of pain, weakness and/or a difference in leg length. The hips play an important role in normal walking and running and, thus, gait is usually significantly affected by hip pathology.

There are two phases in the normal gait cycle: the stance phase, when the foot is on the ground; and the swing phase, when it is moving forward. Most hip problems become apparent in the stance phase.<sup>1</sup> The individual with hip pathology will typically shorten the stance phase and will lean over

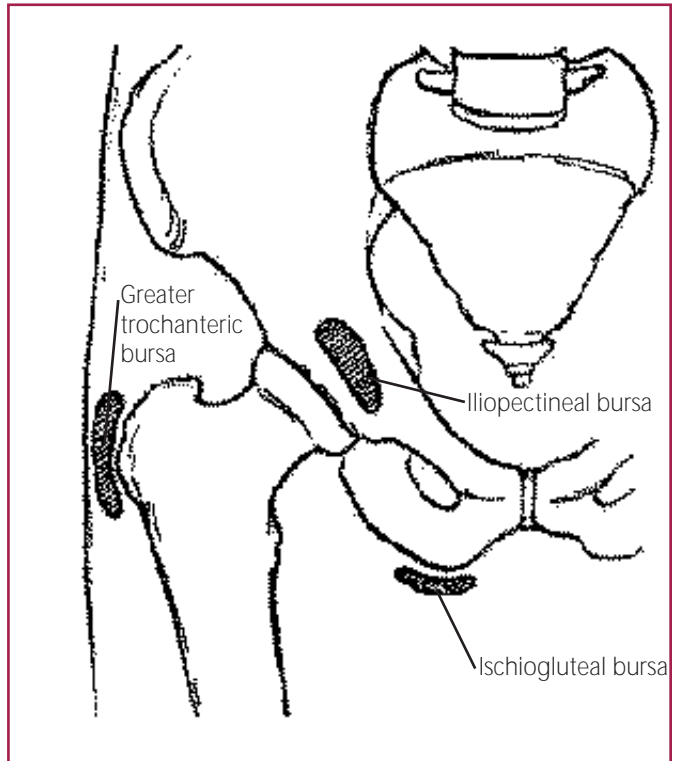


Figure 1. Commonly inflamed bursae in the hip.

the affected hip. The gait will be characterized as antalgic (painful). During the swing phase, the pelvis may not rotate normally around the painful and stiff hip joint.

Reducing the overall load or increasing the surface area over which the load acts can decrease stress on the hip. Canes, crutches and walkers decrease overall load and, therefore, are a common part of the nonsurgical treatment for arthritis of the hip. Properly used, a cane will significantly improve walking distance and comfort.

## **The Approach to Evaluating Hip Pain**

### **History**

Obtaining a good history is important in formulating a differential diagnosis. The

# Adult Hip Pain

Table 1

## CAUSES OF HIP PAIN AS RELATED TO THE SITE OF THE PAIN

	Anterior Hip or Groin Pain	Lateral Hip or Trochanteric Pain	Posterior Hip Pain
Differential Diagnosis	Rule out: hip fracture, septic joint, and avascular necrosis	Rule out: hip fracture, bone tumor, referred pain from lumbar disc herniation	Rule out: sciatic nerve irritation, sacroiliitis due to spondyloarthropathy, lumbar, disc or facet disease
	Other causes: OA, RA, iliopectineal bursitis	Other causes: trochanteric bursitis, OA, radiating from lumbar disc or facet disease	Other causes: muscle strain

history not only helps to focus on hip pathologies, but it may help differentiate hip disease from other conditions, such as “referred pain” from spinal stenosis. The patient with hip pathology often presents with a chief complaint of pain and, therefore, the characteristics of the pain should be explored in detail. The following questions should be addressed:

*Age.* Range of motion decreases with age and different conditions occur at various age groups. For example, elderly women are more prone to osteoporotic femoral neck fractures and suffer more commonly from osteoarthritis (OA).

*Onset.* A gradual onset of pain may suggest a degenerative arthritic process, such as OA, whereas a sudden onset may indicate a traumatic etiology.

*Location.* Hip pain can broadly be classified as anterior, lateral or posterior.<sup>4</sup> Table 1 outlines possible conditions causing pain in different regions of the hip. Many serious pathologies can present in any location and, therefore, Table 1 should be used as a guide—not as an independent means—to arrive at a definitive diagnosis.

*Radiation.* Is the pain felt mostly in the groin and along the medial side of the

thigh? Although anterior hip pain may be due to any of the conditions outlined in Table 1, groin and medial thigh pain can simulate L4 nerve root pain. In such circumstances, the back should be examined, as it can be the source of referred hip pain.

*Snapping.* Is there snapping in and around the hip? Snapping of the hip, or coxa saltans, is generally caused by movement of one structure against another. Three common conditions (referred to as “snapping hip syndromes”) are:<sup>5</sup>

- a. Mechanical abnormalities that can result in internal snapping. This occurs at approximately 45 degrees of flexion, when the hip is moving from flexion to extension. The snap, which may be accompanied by pain, is palpated anteriorly; for example, the iliopsoas tendon can slip over the osseous ridge of the lesser trochanter or the anterior acetabulum, causing a snap that is felt/heard during movement. The iliofemoral ligament riding over the femoral head can be another cause of internal snapping.
- b. External snapping is due to a tight ili-otibial band or gluteus maximus tendon riding over the greater tuberosity of the femur. The snapping or popping occurs

during hip flexion and extension, especially if the hip is held in medial rotation. This condition is exacerbated by trochanteric bursitis.

- c. Acetabular labral tears or loose bodies cause intra-articular snapping. In this case, the patient complains of a sharp pain into the groin and anterior thigh, especially during pivoting movements. Passively, clicking may be felt and heard when the extended hip is adducted and laterally rotated.

*Mechanism.* Did the patient fall on the outside/lateral aspect of his/her hip? A fall on the lateral aspect of the hip could indicate a fracture or something more benign, such as trochanteric bursitis. Did they land on their knees? Landing on the knee and jarring the hip may result in a subluxation and/or labral tear. Were they involved in a repetitive type of work? Repetitive loading activities can result in a femoral stress fracture.

*Progression.* To gauge the progression of the pain, the level of functional impairment should be noted. How many blocks could the patient walk prior to the onset of their hip pain? How many blocks can they now walk? Also, ask if the patient is taking any medication(s) for the pain. The type of medication, dosage and frequency will suggest the severity of the pain.

*Exacerbation.* What type of activity exacerbates the pain? For example, trochanteric bursitis often results from abnormal running mechanics with the feet crossing midline (increased adduction), wide pelvis and genu valgum, or running on bankless tracks.

### **Physical Examination**

When examining the hip, the following sequence is useful: inspection, palpation,

range of motion, muscle strength and special tests.

*Inspection.* Much of the patient's hip problem can be assessed from observing gait, curvature of the back, pelvic symmetry and leg length. The following areas should be noted on inspection:

- **Deformity.** With the patient standing, inspect from the front and from behind for any pelvic tilting or rotational deformity. While observing the patient from behind, look for presence of scoliosis; from the side, note if lumbar lordosis is increased, which may indicate a fixed flexion deformity.
- **Gait.** Common abnormal gait patterns associated with hip disease are antalgic and Trendelenburg. To apply the Trendelenburg test, ask the patient to stand on one leg. The hemi-pelvis on the opposite side should remain elevated, indicating functioning adductors on the weight bearing leg. If the hemi-pelvis falls, this is a positive test, which can be caused by gluteal muscle weakness, inhibition from pain or a hip deformity.
- **Leg length.** Measure each leg from the anterior superior iliac spine to the medial malleolus. Leg-length discrepancies indicate hip pathology on the shortened side.

*Palpation.* Because the hip joint is a deep interior structure, careful palpation is necessary to localize the pain and to determine whether the pain radiates elsewhere.

**Canes, crutches and walkers are a common part of the nonsurgical treatment for arthritis of the hip.**



## Adult Hip Pain

**Routine blood work helps determine the presence of a systemic illness that may be underlying the hip pain.**

Palpation is usually performed with the patient supine. Palpate for crepitations by placing fingers over the femoral head, just lateral to the femoral artery below the inguinal ligament. Roll the relaxed leg medially and laterally (internal and external rotation at zero degrees) to detect any crepitations. Ask the patient to lie on his/her side and palpate the greater trochanter and the trochanteric bursa.

*Range of Motion.* The normal range of motion generally decreases with increasing age. The following range of motion tests are useful in determining the presence of hip

pathology. Normal internal rotation is 35 degrees and external rotation is 45 degrees. The normal range for abduction is 45 degrees to 50 degrees.

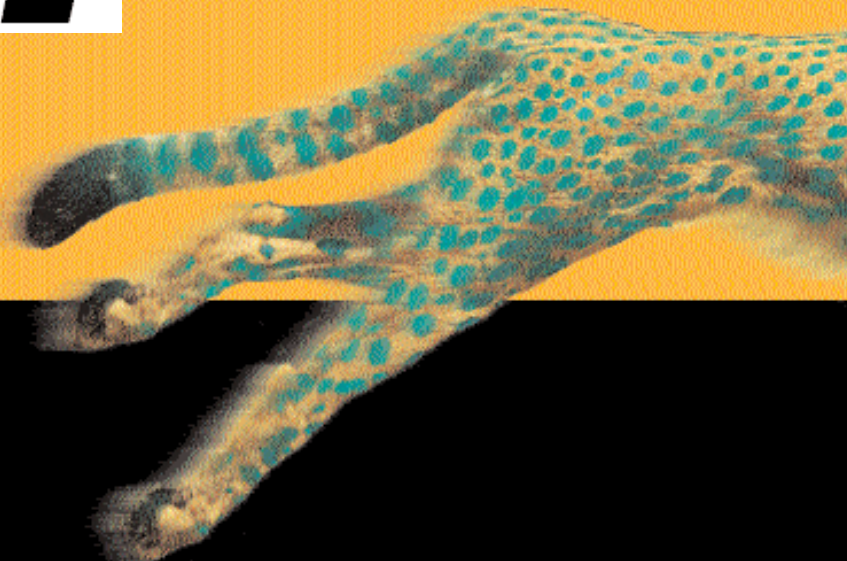
*Manual Muscle Testing.* Look for asymmetry in muscle strength. The affected hip may be weaker. Test the following: flexors (iliopsoas and rectus femoris), extensors (gluteus maximus and hamstrings), abductors (gluteus medius and gluteus minimus) and adductors (adductor longus, magnus and brevis, pectineus and gracilis).

*Special Tests.* These include the Thomas test, Ober's test and the piriformis test.

- Thomas test. With the patient supine, place your hands under the lumbar spine. Obliterate the lumbar lordosis by either passively flexing one hip fully, or ask the patient to actively flex the hip

# Think

# Fast.\*



Prevacid is indicated for short-term treatment of reflux esophagitis and maintenance therapy of healed reflux esophagitis. Most common side effects (> 3%) in short-term studies are headache and diarrhea.

Doses higher than 30 mg per day should not be administered to patients with impaired hepatic function and the elderly.

\*After the first day of therapy, significantly more patients ( $p < 0.05$ ) on Prevacid 30 mg (n = 402) compared to omeprazole 20 mg (n = 418) reported no daytime heartburn (48.7% vs. 37.6%) and nighttime heartburn (62% vs. 52%) in an 8-week randomized, double-blind study in patients with endoscopically diagnosed reflux esophagitis!

Consult Product Monograph for dosage recommendations.

Abbott Laboratories, Limited  
Saint-Laurent, Québec H4S 1Z1  
Product Monograph available on request.

Table 2

## SYNOVIAL FLUID ANALYSIS

	Normal	Inflammatory	Non-Inflammatory	Infectious	Hemorrhagic
Color	Clear	Clear	Opaque	Opaque	Sanguinous
Viscosity	High (due to hyaluronate)	High	Low	Low	Variable
WBC/mm <sup>3</sup>	< 200	< 2000	> 2000	> 50,000	Variable
% PMN	< 25%	< 25%	> 25%	> 50%	Variable
Examples		Traumatic, OA, neuropathic, hypertrophic arthropathy	Seropositives, seronegatives, crystal arthropathies	Septic arthritis	Trauma hemophilia

and hold the leg firmly against the abdomen. Elevation of the opposite thigh suggests a loss of extension in that hip—a fixed flexion deformity.

- Ober's test. This test assesses the tensor *faciae latae* (iliotibial band [IT]) for contracture. Lay the patient on his/her side with the lower leg flexed at the hip



# Adult Hip Pain

Table 3

## INTERPRETING PLAIN RADIOGRAPHS OF THE HIP

	Alignment	Bone Mineralization	Articular Cartilage	Soft Tissue
What to look for	<ul style="list-style-type: none"> <li>• Fracture</li> <li>• Dislocation</li> <li>• Angle of inclination</li> <li>• Acetabular index</li> <li>• Femoral offset and abductor lever arm</li> <li>• The inter-teardrop line</li> <li>• Teardrop sign</li> <li>• Bryant's triangle and Nelaton's line</li> <li>• Shenton line</li> </ul>	<ul style="list-style-type: none"> <li>• Osteoporosis</li> <li>• Osteopenia</li> <li>• Avascular necrosis</li> </ul>	<ul style="list-style-type: none"> <li>• Joint-space narrowing</li> <li>• Osteophytes</li> <li>• Subchondral sclerosis</li> <li>• Subchondral cysts</li> <li>• Subluxations</li> </ul>	<ul style="list-style-type: none"> <li>• Signs of effusion</li> </ul>

and knee for stability. Then passively abduct and extend the patient's upper leg, with the knee straight or flexed to 90 degrees. Slowly lower the upper limb; if a contracture is present, the leg will remain abducted and not fall to the table. It is important to extend the hip

slightly so that the IT band passes over the greater trochanter.

- Piriformis test.

The patient is in the side lying position.

The patient flexes the test hip to 60 degrees, with the

knee flexed. The examiner stabilizes the hip with one hand and applies a downward pressure to the knee. If the piriformis muscle is tight, pain is elicited in that muscle. If the piriformis muscle is pinching the sciatic nerve, pain results in the buttock, and sciatica may be

experienced by the patient. In about 15% of the population, the sciatic nerve, all or in part, passes through the piriformis muscle rather than below it. It is these people who are more likely to suffer from piriformis syndrome.<sup>5</sup>

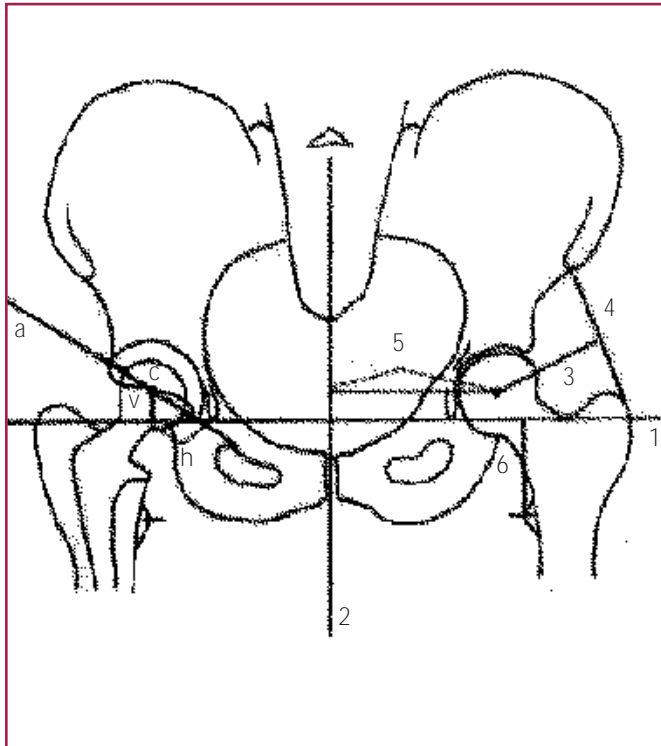
### Laboratory Investigations

Not all lab investigations need to be done with every case of adult hip pain. Certain tests, such as rheumatoid factor and anti-nuclear antibodies, are critical in diagnosing systemic autoimmune diseases. The general lab work that can be done as part of hip pain assessment includes blood work and synovial fluid analysis.

Routine blood work helps in determining the presence of a systemic illness that may be underlying the hip pain. More commonly, the clinician looks for elevated white count for signs of infection; for example, in a septic hip. It also is useful to look for auto-antibodies if an autoimmune disease is suspected.

## Radiography is the primary imaging tool for disease of the adult hip.





- a = The line that crosses the lateral and medial margins of the base of the acetabulum.
- c = Center of the hip.
- h = Horizontal position of the hip center. This distance is from the distal tip of the teardrop to a perpendicular line dropped from the hip center.
- v = The vertical position of the hip center. This is the distance from the inter-teardrop line to the hip center.
- 1 = The inter-teardrop line. This is the horizontal line that joins the right and left distal margins of the teardrop. The angle formed by line a intersecting line 1 is the angle of acetabular inclination.
- 2 = Midline.
- 3 = Abductor lever arm.
- 4 = The approximate length of abductor muscles.
- 5 = The body weight lever arm.
- 6 = Proximal femur length. This is the distance from the inter-teardrop line to the lesser trochanter.

Figure 2. Alignment measurements of the hip.

The presence of rheumatoid factor (RF) can confirm a diagnosis of rheumatoid arthritis. Positive RF and anti-nuclear auto-antibodies can also indicate the presence of lupus.

Synovial fluid analysis provides a definitive diagnosis for infections and crystal arthropathies. Normally, the fluid is colorless (or straw-colored), with a protein concentration that is one-third plasma protein

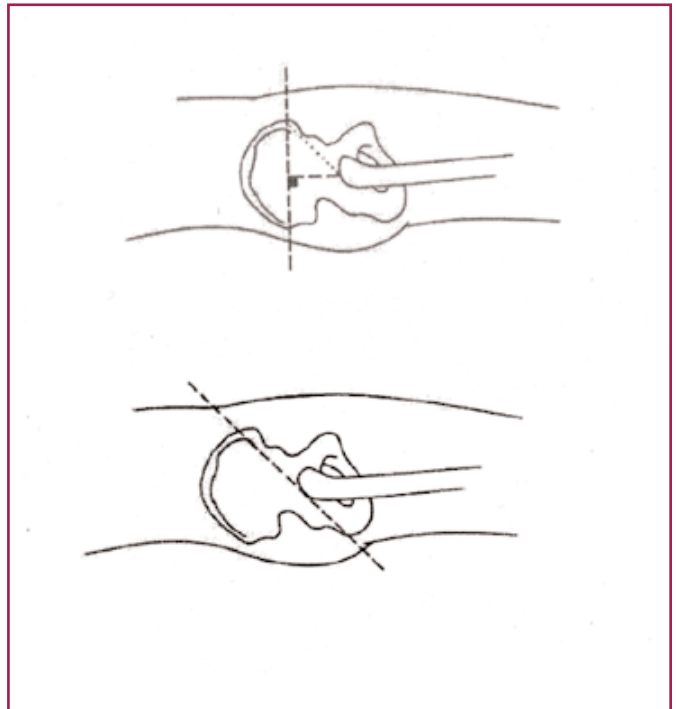


Figure 3. Bryant's triangle (top) and Nelaton's line (bottom).

concentration. The three most important aspects of synovial fluid analysis are: 1) cell count and differential; 2) crystal examination; and 3) culture and gram stain. Table 2 illustrates the characteristic features of synovial fluid in various hip conditions.

### *Imaging of the Hip*

There are many imaging modalities used to view the hip. Frequently used imaging tools include plain radiographs, bone scans, computed tomography and magnetic resonance imaging (MRI). An approach to plain films will be discussed in detail and indications for the other imaging tools will be addressed below.

Radiography is the primary imaging tool for disease of the adult hip. Routine hip views on x-ray are anteroposterior (AP) of the pelvis, AP of the hip and lateral films. Specialized views provide clearer

Table 4

## SELECTING IMAGING TOOLS FOR SPECIFIC HIP CONDITIONS

Condition	Ultra-sound	X-ray	Bone Scan	Tomography	MRI	CT	Arteriography & Venography
Fracture	---	*	* (stress)	* (stress)	* (pelvic)	* (pelvic)	---
Trauma	---	*	---	---	*	*	---
Avascular Necrosis	---	*	*	---	*	*	*
Degenerative Arthritis	---	*	---	---	---	---	---
Tumors	---	*	*	---	*	*	*
Soft Tissue Injury	*	*	---	---	---	*	---
Osteoporosis	---	*	*	---	*	---	---

\* = used for this hip condition

--- = not often used for this hip condition

images of certain aspects of the joint; for example, the frog-leg lateral gives better view of the anterolateral femoral head and is useful in suspected avascular necrosis (AVN). Forty degrees cephalad AP is useful for subtle femoral neck fractures and pubic fractures.

## MRI is the most sensitive and specific modality for detecting AVN of the hip.

Generally, four areas need to be considered when viewing a plain radiograph: alignment, bone mineralization, articular cartilage and soft tissue. Table 3 indicates specific characteristics to look for when interpreting plain films of the hip.

*Alignment.* It is important to compare the alignment of both sides. Asymmetry may suggest a fracture dislocation on the affected side. There are alignment measurements on

the AP pelvis that are important. Abnormalities in these measurements would indicate fracture/dislocations that would not have been identified on a gross examination of the x-ray (Figure 2).<sup>3</sup> An “absent teardrop” on x-ray is suspicious for metastatic disease, as with an absent (nonvisualized) pedicle on lumbar radiographs. Bryant’s triangle and Nelaton’s line are measurements that can be applied to a true lateral x-ray of the hip. A positive finding in each case is suggestive of a dislocated hip (Figure 3).<sup>2</sup>

Shenton’s line is a curved line that can be drawn on an AP pelvis radiograph from the medial edge of the femur, arcing smoothly upwards and then down to meet the inferior edge of the pubis. If this line is discontinuous, a dislocation or fracture-dislocation exists.

*Bony Mineralization.* Conditions that can be detected as changes in bony miner-

alization about the hip include inflammatory synovitis, osteoporosis and AVN. A loss of the sharp cortical line of the epiphysis is indicative of inflammatory synovitis, which is associated with rheumatic diseases. In osteoporosis, there is a thinning of the cortex and loss of trabeculae. The term osteopenia describes local x-ray findings in the absence of widespread bone density changes. Note that osteopenia is not recognizable on plain films until there has been a 40% loss in bone mineral density.<sup>6</sup>

Plain film indicators of AVN are scattered lucencies and areas of sclerosis. On the frog-leg view, there can be breaks in the cortex and the characteristic rim sign (a subcortical black lucent line). At a later stage, collapse of the femoral head is observed. Although x-ray can show signs of AVN, MRI is the most sensitive tool in diagnosing this condition.

**Cartilage.** Articular cartilage is normally radiolucent and, therefore, an x-ray of a normal hip joint shows a clear area of joint space. Changes that show narrowed joint space are indicative of a loss of articular cartilage. Narrowed or loss of joint space

is one of the four cardinal features of OA on plain radiograph. The others are presence of osteophytes, subchondral sclerosis and subchondral bone cysts.

**Soft Tissues.** Joint effusions at the hip are difficult to diagnose due to the deeply situated nature of the hip capsule and its relative nondistensibility. Three different radiographic signs indicate fluid in the hip joint:<sup>2</sup>

1. Lateral dislocation of the femoral head. This is common in juvenile RA. It takes a large effusion to sublaxate or dislocate the femoral head out of the acetabulum.
2. Absence of a vacuum effect. This technique can detect small effusions, and is accomplished by providing manual traction to the hip while the x-ray is being taken. In a normal hip, traction creates a negative pressure in the joint and is observed as a radiolucent crescent between the joint surfaces. This phenomenon does not occur when there is extra fluid in the joint.
3. Demineralization of subchondral bone. Fading of the sharp subchondral white

When you see genital herpes, think Famvir.

It has been estimated that 7 out of 10 genital herpes sufferers go undiagnosed.\*

Famvir is indicated to treat or suppress recurrent episodes of genital herpes in immunocompetent adults. Therapy should be initiated during the prodrome or as soon as possible after the onset of lesions.

Most common adverse reactions reported with Famvir in clinical trials were headache and nausea. In patients with moderately or severely reduced renal function, dosage reduction is recommended.

See prescribing information for more information.

1. Cohen DN et al. Herpes Famvir® still a cause for concern. *Am J Ther* 2001;20(3):17-20.

\*Registered trademark of Novartis AG.

Episodic: 125 mg BID for 5 days, suppression 250 mg BID

 **NOVARTIS** Health Research & Innovation  
From Science to Life

 **FAMVIR**  
famciclovir

**FAMVIR**  
famciclovir

line of the femoral head is indicative of an inflammatory synovitis. The radiographic abnormality is caused by demineralization, which results in a fuzzy, ill-defined outline and apparent joint-space widening.

Calcification within soft tissue, on x-ray, also indicates abnormality in the hip joint. It may be seen in muscle, around the joint capsule, and in bursa and tendons (calcific bursitis or tendinitis). The finding of calcification is fairly nonspecific, but can suggest an underlying process like rheumatoid arthritis, systemic lupus erythematosus, heterotopic ossification or a response to past trauma.

### *Nuclear Imaging (Bone Scan)*

In clinical situations where the physical exam and x-ray do not help localize the source of pain, bone scans are a useful guide in locating the probable area of pathology. Nuclear imaging indicates regions of increased metabolic activity ("hot spots") by an increased uptake of a radioactive tracer. It is useful in detecting bony metastatic disease, AVN, arthritis and Paget's disease.

### *Computed Tomography*

The most common use of computed tomography (CT) is to image the hip joint following trauma. Pelvic/acetabular fractures, osseous sequelae of hip dislocation, and intra-articular osseous fragments are better visualized by CT than by plain radiography or tomography.<sup>7</sup> The greater tissue contrast of CT allows detection of peri-articular pathology related to trauma, including characterizing deep retroperitoneal hematomas and peripheral deglov-

ing injuries.<sup>3,8</sup> CT also is useful in characterizing calcifications seen by plain radiography. This may include tumor matrix within bone or characterizing soft tissue calcification or ossification.

### *Magnetic Resonance Imaging*

MRI is the most sensitive and specific modality for detecting AVN of the hip. MRI is useful in detecting soft-tissue lesions (including tumors), transient osteoporosis, synovial pit, bone cysts and stress fractures. Compared to CT scan, MRI is better for imaging medullary bone and soft tissues, and CT is better for imaging cortical bone.<sup>7</sup>

Of the various imaging tools, the plain radiograph is generally first used. If higher resolution scans are required, a CT scan is usually ordered before an MRI. There is no universal algorithm for how to select imaging modalities. Table 4, however, outlines some clinical scenarios where certain images are more advantageous than others. **Dx**

#### References

1. Balderston R, Rothman R, Booth R, et al: The Hip. Lea & Febiger, Philadelphia, 1992, pp. 234-6.
2. Fagerson T: The Hip Handbook. Butterworth-Heinemann, Boston, 1998, pp. 119-24.
3. Callaghan JJ, Rosenberg AG, Rubash HE: The Adult Hip. Volume 1. Lippincott-Raven, Philadelphia, 1998, pp. 456-67.
4. Roberts N, Williams R: Hip pain: Systematic approach to diagnosis. *Primary Care* 1988;15:783-93.
5. Magee DJ: Orthopedic Physical Assessment. W.B. Saunders, Philadelphia, 1992, pp. 333-70.
6. Hayes WC, Myers ER, Robinovitch SN, et al: Etiology and prevention of age-related hip fractures. *Bone* 1996; 80:77s-86s.
7. Lang P, Genant H, Jergesen H, et al: Imaging of the hip joint: Computed tomography versus magnetic resonance imaging. *Clinical Orthopedics and Related Research* 1992; 274:135-51.
8. Kalb RL: Evaluation and treatment of hip pain. *Hospital Practice* 1998; 33(9):131-5.