



Photo Diagnosis

Illustrated quizzes on problems seen in everyday practice

Case 1



New Pink Lesion

A 56-year-old male had some sort of lesion (he doesn't recall what) on his shoulder excised two years ago. There is now a new area of pinkness at the edge of the scar.

Questions

1. What is your diagnosis?
2. What demographic profile is often affected by this condition?
3. How would you manage this patient?

Answers

1. Superficial basal cell carcinoma (BCC)
2. Individuals (often older than 40) with chronic sun exposure often develop this lesion, typically on the trunk.
3. Electrodesiccation and curettage or simple excision are recommended. You can also consider topical imiquimod or 5-fluorouracil and, less commonly, radiation to treat the affected area.

Provided by: Dr. Benjamin Barankin

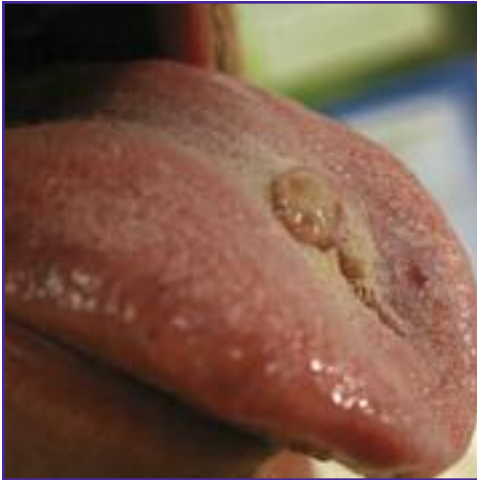Share your photos and diagnoses with us!

Do you have a photo diagnosis? Send us your photo and a brief text explaining the presentation of the illness, your diagnosis and treatment and receive \$25 per item if it is published.

The Canadian Journal of Diagnosis
6500 Trans-Canada Highway, Suite 310
Pointe-Claire, Québec H9R 0A5

Email: diagnosis@sta.ca
Fax: (888) 695-8554

Case 2



Bleeding Tongue Lesion

A 54 year-old male, smoker has developed a lesion over the dorsum of his tongue. It has been growing rapidly and bleeds easily.

Questions

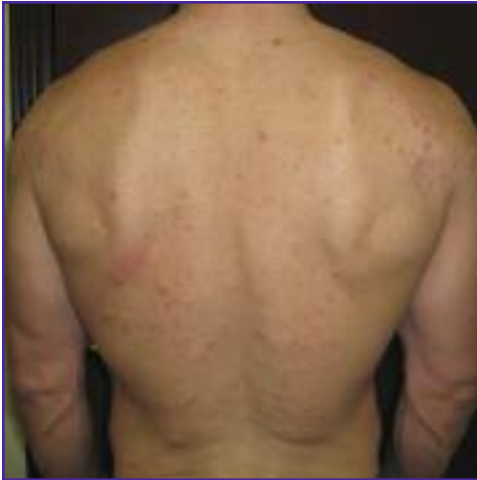1. What is the management?
2. What is the diagnosis?
3. What is the significance?

Answers

1. Biopsy of the lesion
2. Biopsy showed lobular capillary hemangioma (pyogenic granuloma).
3. Pyogenic granuloma (PG) is a benign non-neoplastic mucocutaneous lesion. It is a reactionary response to constant, minor trauma and might be related to hormonal changes. In the mouth, PG is manifested as a sessile or pedunculated, resilient, erythematous, exophytic, and painful papule or nodule with a smooth or lobulated surface that bleeds easily. PG preferentially affects the gingiva, but it may also occur on the lips, tongue, oral mucosa, and palate. The most common treatment is surgical excision.

Provided by: Dr. Jerzy K. Pawlak and Dr. Ted Krocak

Case 3

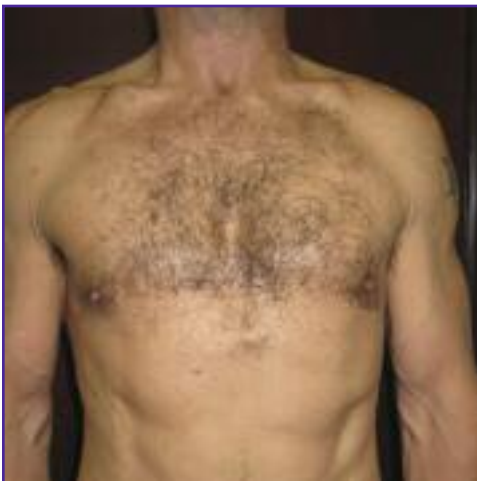

Vesicular and Pustular Eruption

A 44-year-old male presents with a four-week history of a pruritic vesicular and pustular eruption on the chest and back.

Questions

1. What is the diagnosis?
2. Who is most commonly affected by this condition?
3. What are the treatments?

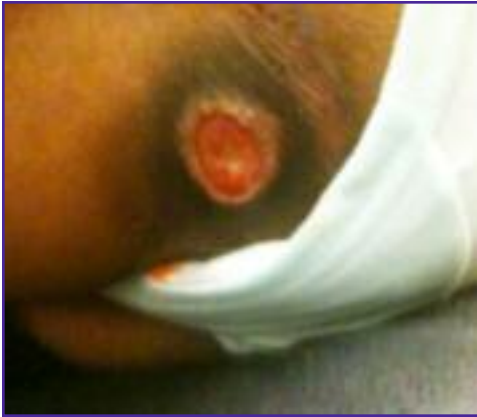

Answers

1. Transient acantholytic dermatosis (Grover's disease)
2. This condition most commonly affects middle-aged Caucasian males. Men are affected three times more often than women.
3. Potent topical corticosteroids are effective in controlling pruritus that is associated with this condition. Oral corticosteroids, UVB phototherapy, and methotrexate have all been reported to be effective in recalcitrant cases.

Provided by: Dr. Francesca Cheung

Case 4



Sore on the Buttock

A 45-year-old lady presents complaining of a sore on her buttock. It has been there for one year but has been worsening recently. Polysporin applications are not helping. She has been wheelchair bound for two years due to a failed spinal surgery, resulting in paraplegia.

Questions

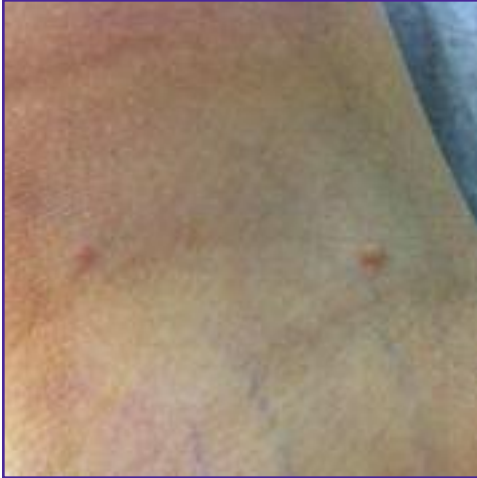1. What is your diagnosis?
2. What are the stages of this condition?
3. How would you manage this?

Answers

1. Commonly referred to as pressure sores, or bedsores, decubitus ulcers typically occur over bony prominences below the waistline as a result of pressure, friction, or excess moisture.
2. Decubitus ulcers are classified into four stages based on their degree of depth and damage. Stage I involves intact skin with overlying non-blanching erythema. Partial-thickness skin loss, affecting the epidermis with or without the dermis, is classified as stage II. Stage III is called full-thickness skin loss, because it involves extension into subcutaneous tissue. Stage IV is the most severe and includes full-thickness skin loss with extensive necrosis or damage to muscle, bone, or supporting tissues.
3. If pressure is regularly relieved, tissue recovery can occur, and, therefore, management begins with repositioning and support surfaces. Wound care with cleansing, debridement, and appropriate dressings is also important. Pain management with topical anaesthetics, NSAIDs, and opioids may be required. Screening for nutritional deficiencies is important, and adequate dietary intake of protein can help with healing. Finally, surgery may be necessary in more severe cases.

Provided by: Dr. Kimmy Goyal and Dr. Ankush Goyal

Case 5



Asymptomatic Papules

An 11-year-old boy presents with asymptomatic papules around his buttocks and in the popliteal fossa bilaterally.

Questions

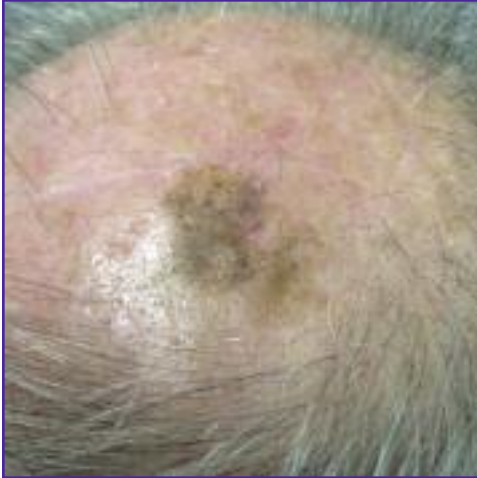1. What is the diagnosis?
2. What is the significance?
3. What is the treatment?

Answers

1. Molluscum contagiosum
2. Molluscum contagiosum is a cutaneous eruption caused by a poxvirus of the Molluscipox genus in the Poxviridae family. The virus can be transmitted through close physical contact, autoinoculation, and fomites. Typically, molluscum contagiosum presents as asymptomatic, discrete, smooth, dome-shaped, waxy papules with central umbilication from which a plug of cheesy material can be expressed. The colour can also be pearly white, yellow, or flesh-coloured. The lesions can be cosmetically unsightly and embarrassing. Other complications include secondary bacterial infection, conjunctivitis, and superficial punctate keratitis. Secondary bacterial infection is often secondary to scratching-induced impetiginization.
3. No single intervention has been convincingly effective in the treatment of molluscum contagiosum. Some authors suggest benign neglect of the lesions and awaiting spontaneous resolution. However, most authors suggest active treatment of lesions for cosmetic reasons, social stigma associated with visible lesions, alleviating discomfort, including itching, or concerns of transmission and autoinoculation. Active treatments may be mechanical (*e.g.*, curettage, cryotherapy with liquid nitrogen, pulsed dye laser therapy, carbon dioxide laser therapy), chemical (*e.g.*, cantharidin, tretinoin, podophyllotoxin, trichloroacetic acid, potassium hydroxide, lactic acid, glycolic acid, salicylic acid), immunomodulating treatments (*e.g.*, imiquimod, cimetidine), and anti-viral medications (cidofovir).

Provided by: Ms. Shirley Chan and Dr. Alexander K.C. Leung

Case 6



Slowly Evolving Pigmented Patch

A 67-year-old male presents with a slowly progressing pigmented lesion on the scalp, which he first noticed five years earlier.

Questions

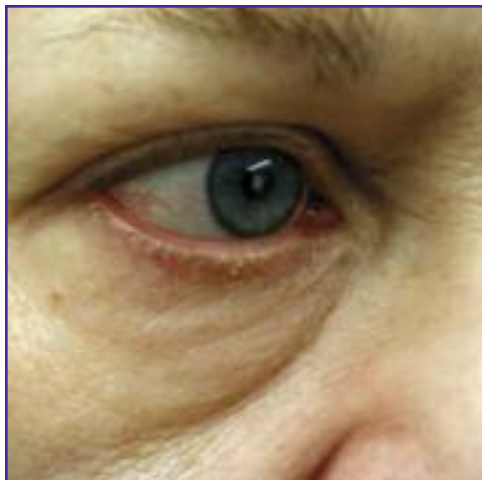
1. What is the diagnosis?
2. What is the significance?
3. What is the treatment?

Answers

1. Lentigo maligna
2. Lentigo maligna is a type of melanoma in situ on a background of sun-damaged skin with radial growth in the epidermis only. These large, flat, pigmented lesions with irregular shape evolve slowly over 5 to 20 years and are typically found on sun-exposed sites, such as the face, neck, or scalp. Approximately 3 to 10% of lentigo maligna cases develop into invasive lentigo maligna melanoma by growing vertically into the dermis.
3. Any suspicion of lentigo maligna should be biopsied. Once the diagnosis of lentigo maligna is made, the patient should be referred for surgical excision.

Provided by: Dr. Kristy Bailey and Dr. Daniel Mckee

Case 7



Deteriorating Vision

This 61-year-old female presents to the office complaining that the vision in her right eye is deteriorating.

Questions

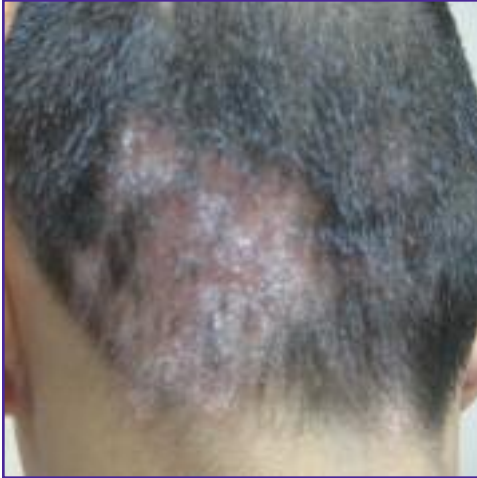1. What is the diagnosis?
2. What is the management?

Answers

1. Right eye cataract
2. An ophthalmology consultation should be sought.

Provided by: Dr. Jerzy K. Pawlak and Dr. Ted Krocak

Case 8



Worsening Scalp Rash

A 14-year-old male presents with a two-month history of pruritic and scaly erythematous plaques on the scalp. Previous treatment with a lotion containing betamethasone dipropionate did not provide any improvement.

Questions

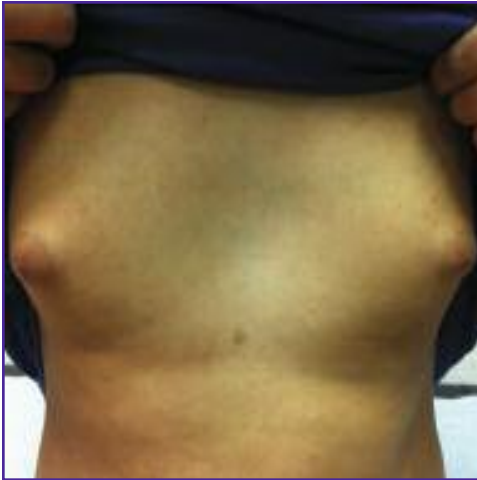
1. What is the diagnosis?
2. What are the investigations?
3. What is the treatment?

Answers

1. The diagnosis is tinea capitis.
2. Mycologic investigations with potassium hydroxide microscopic examination and culture of scalp scrapings or hair pluckings from lesions will be helpful.
3. Topical antifungal agents alone are usually ineffective. Systemic antifungal agents, such as terbinafine and itraconazole, are most commonly used.

Provided by: Dr. Francesca Cheung

Case 9



Breast Tissue Growth

A 13-year-old, slightly overweight boy presents with a one-year history of breast tissue growth. He is otherwise well. On exam, he has enlarged glandular tissue bilaterally with normal testicular size.

Questions

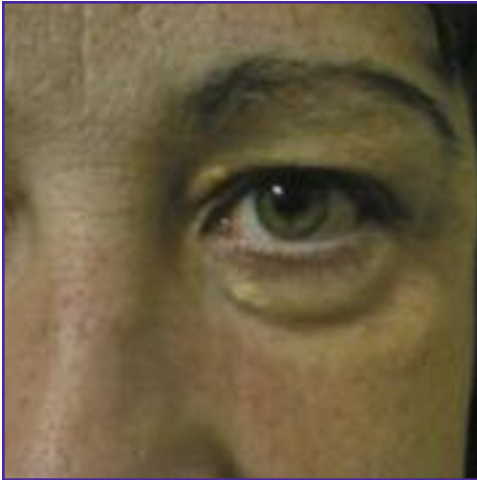
1. What is the diagnosis?
2. What is the significance?
3. What is the treatment?

Answers

1. Pubertal gynecomastia
2. Pubertal gynecomastia refers to a benign, physiological proliferation of the male glandular breast tissue at the time of puberty. The affected adolescent is otherwise healthy. The condition is usually bilateral but may affect one breast more than the other. Secondary sexual characteristics, such as pubic hair development and testicular enlargement, are characteristically present for at least six months prior to the onset of gynecomastia. During puberty, serum estradiol concentrations rise before testosterone, and the transient physiological imbalance is largely responsible for pubertal gynecomastia. Adrenal androgens are increased in early adolescence, and these androgens can be converted to estrogens peripherally. Aromatase is the key enzyme for estrogen biosynthesis. Other causes of gynecomastia include drugs (*e.g.*, digitalis, spironolactone), adrenal disorders (*e.g.*, feminizing adrenal tumours), hepatic disorders (*e.g.*, cirrhosis), malnutrition, hypogonadism, and thyroid disorders (*e.g.*, hypothyroidism, hyperthyroidism).
3. Treatment consists mainly of reassuring the patient that the condition is benign and that spontaneous resolution usually occurs within three years. Selective estrogen receptor modulators, such as raloxifene and tamoxifen, may be used to treat severe pubertal gynecomastia. Reduction mammoplasty may be considered for those cases that fail to respond to medical treatment and in those that cause significant psychological disturbance and embarrassment.

Provided by: Ms. Shirley Chan and Dr. Alexander K.C. Leung

Case 10



Eyelid Lesion

A 43-year-old, obese, white female comes to the clinic concerned about a worsening lesion on her left eyelid. It has been there for years. On lab testing, her total cholesterol was 7.4 mmol/L.

Questions

1. What is the diagnosis?
2. What is the etiology?
3. What is the appropriate management?

Answers

1. Xanthelasma is a common type of xanthoma that affects the eyelids.
2. Xanthomas are typically a result of hyperlipidemia; however, half of all patients with xanthelasmas have normal lipid levels. Macrophages containing lipid droplets (xanthoma cells) are seen on histopathology.
3. Cholesterol levels should be measured, and, if elevated, patients should be treated appropriately. Treating the underlying hyperlipidemia may cause the lesions to regress. Those with normal lipid profiles may be treated for cosmetic reasons with surgical excision, cryotherapy, or trichloroacetic acid or laser therapy. In these cases, the lesions often recur despite treatment. **Dx**

Provided by: Dr. Kimmy Goyal and Dr. Ankush Goyal